



PATIENT

Oliver Hechinger

SPECIES

Canine

BREED

Saint Bernard

SEX

Male Neutered

AGE

8.3 years

WEIGHT

130lbs

INTERPRETED BY

Maggie Machen Lamy,
DVM, DACVIM
(Cardiology)

IMAGING PERFORMED BY

Loetitia St-Jacques,
LVT/RVT

HOSPITAL NAME

Sierra Pet Clinic

REFERRING VET

Dr. Sperka

INVOICE

28368

DATE

1/16/23

PRESENTING CLINICAL SIGNS

History: Grade 4/6 heart murmur with intermittent galloping pulse. Asymptomatic. Diet is Darwin's balanced raw, freeze dried fresh, eggs, yogurt, sardines. Blood pressures 114/72, 128/65, 116/76mmHg. Bloodwork WNL Taurine checked 10/2021 WNL.

-Current medications: Trazodone 200mg BID, Gabapentin 600mg BID prior to scan. Proin 145 SID. Pertinent previous echo findings (2016 EL): nsf with minor TR

ECHOCARDIOGRAM FINDINGS

2D, m-mode, color flow and doppler imaging is available. Severe left ventricular dilation with diminished systolic function. Decreased LV wall thickness with increased sphericity. Severe left atrial enlargement. The mitral valve appears normal in form and function, with no obvious prolapse into the left atrial lumen. Mild central mitral regurgitation secondary to annular stretch. Moderate tricuspid regurgitation. Moderate right atrial and ventricular dilation. TR velocity consistent with mild pulmonary hypertension. The aortic valve is normal in morphology and mobility. No subvalvular ridge present; normal LVOT velocity. No aortic insufficiency. Normal pulmonic valve with no pulmonic insufficiency seen. Scant pericardial and no pleural effusion noted. No obvious cardiac tumors.

CARDIAC CHART

CANINE CARDIAC PARAMETERS	MR VMAX (m/s)	TR VMAX (m/s)	LA/AO (Boon method)	LA/AO (Heart Base; Swe)	FS (%)	EF (%)	EPSS (cm)
NORMAL PARAMETER	4.5-5.5	<2.7	1.3	<1.6	28-40	40-100	<0.6
PATIENT	4.6	2.9	NM	2.1	15	35	1.3
CANINE CARDIAC PARAMETERS	HR (BPM)	AV VMAX (m/s)	PV MAX (m/s)	BODY WEIGHT (kg)	LA 2D short axis Base view (cm)	LVIDd Avg; 2D and m-mode short axis (cm)	LVIDs Avg; 2D and m-mode short axis (cm)
NORMAL PARAMETER	50-100	0.7-1.7	0.7-1.6	BELOW	BELOW	BELOW	BELOW
PATIENT		0.7	0.50	59.0	6.3	7.8	6.6
*Normal chamber parameters expressed as a mean value (SD)				3	1.27 (5.3)	2.46 (2.46)	1.36 (5.5)
BODY WEIGHT DEPENDENT PARAMETERS				5	1.40 (4.5)	2.74 (5.2)	1.60 (4.7)
<i>*Note: All measurements based upon multi-modal images and methods. An average value is reported.</i>				10	1.50 (3.8)	3.27 (3.5)	2.06 (3.1)
				15	1.83 (2.0)	3.71 (2.4)	2.43 (2.1)
				20	2.02 (1.9)	4.14 (2.2)	2.80 (2.0)
				25	2.18 (2.4)	4.48 (2.9)	3.10 (2.5)
				30	2.33 (3.3)	4.83 (3.9)	3.39 (3.4)
				35	2.48 (4.3)	5.17 (5.0)	3.69 (4.5)
				40	2.62 (5.2)	5.48 (6.1)	3.96 (5.4)
				50	2.88 (7.1)	6.07 (8.3)	4.46 (7.4)

INTERPRETATION OF THE FINDINGS & FURTHER RECOMMENDATIONS

Unfortunately, this patient has developed significant cardiomyopathy and systolic dysfunction. This is causing dilation and volume overload of both the left and right heart resulting in insufficiency of the mitral and tricuspid valves. The severity of dysfunction and pump failure is severe, and the patient is at high risk for decompensating into congestive failure. Patient will always be at risk for right and/or left-sided CHF, development of arrhythmias/syncope and/or



PATIENT

Oliver Hechinger

sudden death going forward. The finding of scant pericardial effusion is concerning for early CHF even without reported clinical signs.

SPECIES

Canine

Systolic failure can be primary in nature (DCM) or secondary to taurine deficiency, myocarditis, hypothyroidism, tachycardia-induced cardiomyopathy, or infiltrative disease such as lymphoma. While primary disease is certainly possible, consider testing for primary causes that may be treatable. A troponin (cTnl) level can be submitted to further investigate infiltrative/inflammatory contribution (myocarditis). Even with a normal taurine level, the diet is somewhat concerning given the unusual nature of FDA reports. A diet change to a standard option could be considered, although likely of little utility. Finally, further systemic evaluation for underlying infiltrative contribution such as neoplasia is also reasonable (abdominal ultrasound, etc.).

BREED

Saint Bernard

SEX

Male Neutered

Regardless of cause, prognosis is guarded to poor at this stage in the disease process, with an average survival time of <6 months. The only treatable cause of systolic failure is diet/taurine deficiency, which is uncommon on commercially formulated dog foods. If the diet is of concern, highly recommend immediate diet change and taurine supplement regardless of blood taurine results. Please see the FDA website for more information.

AGE

8.3 years

Immediate institution of full cardiac supportive medications is recommended as below due to high risk for decompensation. Cases of systolic failure are at high risk for malignant tachyarrhythmias (such as VT or rapid AF) and sudden death, and this should be expressed to the owner. Activity restriction is advised, and a baseline ECG recommended.

WEIGHT

130lbs

Elective anesthesia is not advised due to high risk for complications.

INTERPRETED BY

Maggie Machen Lamy,
DVM, DACVIM
(Cardiology)

Omega fatty acid supplementation and mild salt restriction may be of some long-term benefit. Monitor for development of a cough, worsening labored breathing, abdominal distention, exercise intolerance or collapse episodes in the future. Monitoring of sleeping breathing rates at home is recommended to assess response to medications and recurrence of CHF in the future.

IMAGING PERFORMED BY

Loetitia St-Jacques,
LVT/RVT

PLAN:

Baseline ECG recommended. Initiate aldosterone antagonist Spironolactone 1-2mg/kg PO q12h. Institute furosemide 1mg/kg PO q12h. Institute Pimobendan 0.3mg/kg PO q12h. Institute taurine 1000mg PO q12h (despite normal taurine levels).

HOSPITAL NAME

Sierra Pet Clinic

Monitor a renal panel and blood pressure in 1-2 weeks to ensure tolerance. If BP >130mmHg, institute ACEI 0.5mg/kg PO q12h.

REFERRING VET

Dr. Sperka

A recheck echocardiogram is recommended in 4-6 months to screen for progression, sooner if clinical issues arise in the interim.

INVOICE

28368

DATE

1/16/23



PATIENT

Oliver Hechinger

SPECIES

Canine

BREED

Saint Bernard

SEX

Male Neutered

AGE

8.3 years

WEIGHT

130lbs

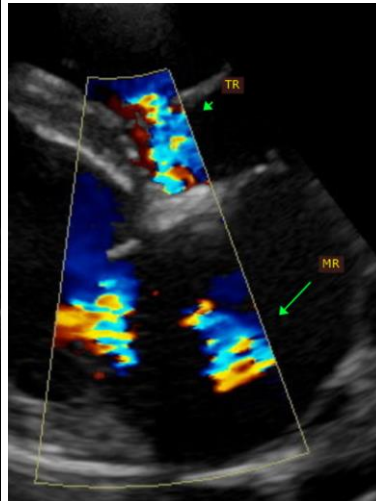
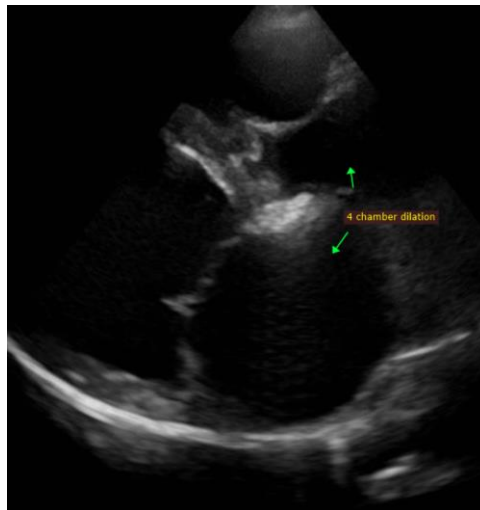
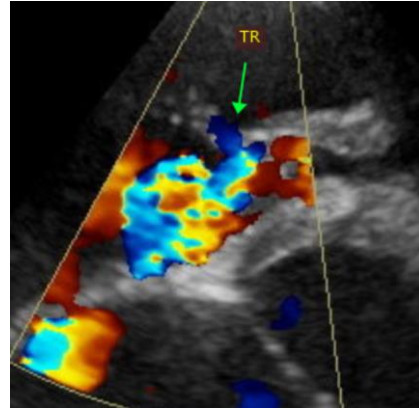
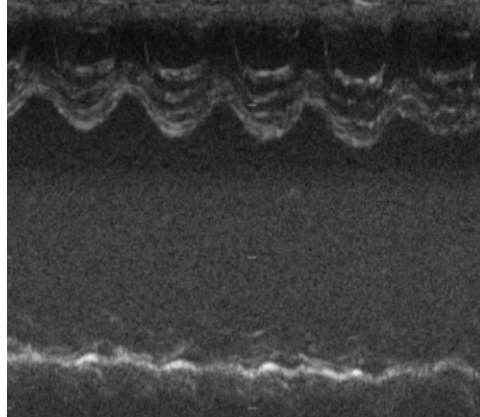
INTERPRETED BY

Maggie Machen Lamy,
DVM, DACVIM
(Cardiology)

IMAGING PERFORMED BY

Loetitia St-Jacques,
LVT/RVT

IMAGES



HOSPITAL NAME

Sierra Pet Clinic

REFERRING VET

Dr. Sperka

INVOICE

28368

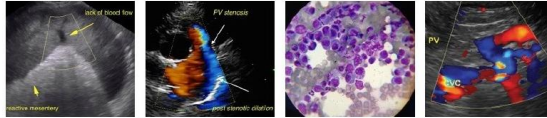
DATE

1/16/23

The information and recommendations provided are based on the images presented by the referring veterinarian. No evaluation can be communicated regarding pathology that was not visible in the image/video clips provided.

Thank you for this referral. This report was generated using transcription software, and minor dictation errors may be present. If the clinical or image interpretation does not parallel your findings or if I can be of any further assistance, please contact me.

Maggie Machen Lamy, DVM
Diplomate of the American College of Veterinary Internal Medicine (Cardiology)
info@sonopath.com



Portable Animal Western Sonography, Inc.

IMAGING PERFORMED BY

pawsonography@gmail.com  530-786-8340

PATIENT

Oliver Hechinger

SPECIES

Canine

BREED

Saint Bernard

SEX

Male Neutered

AGE

8.3 years

WEIGHT

130lbs

INTERPRETED BY

Maggie Machen Lamy,
DVM, DACVIM
(Cardiology)

IMAGING PERFORMED BY

Loetitia St-Jacques,
LVT/RVT

HOSPITAL NAME

Sierra Pet Clinic

REFERRING VET

Dr. Sperka

INVOICE

28368

DATE

1/16/23